RĪGAS DZEMDĪBU NAMS

POLITECNICO DI TORINO 1859 1906

univerzitetni klinični center ljubljana

Compagnia di San Paolo

TASI 2

# CHANGES OF EXTERNAL ANAL SPHINCTER INNERVATION PATTERN AFTER DELIVERY


K. Drusany Starič,
Vita Začesta, A. Lukanović R. Merletti


INTERNATIONAL ACCREDITATION Healthcare

EFQM Recognised for excellence 4 star

ISO 9001 BUREAU VERITAS Certification

BUREAU VERITAS 1828

# WHAT CAN HAPPEN WITH ANAL SPHINCTER AFTER DELIVERY?

# INTACT ANAL SPHINCTER

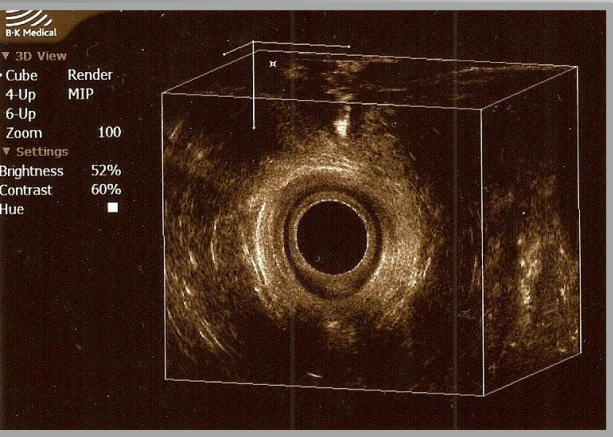


# ANAL SPHINCTER DAMAGE

27%-AFTER FIRST DELIVERY

8,5 %-MULTIPARAE

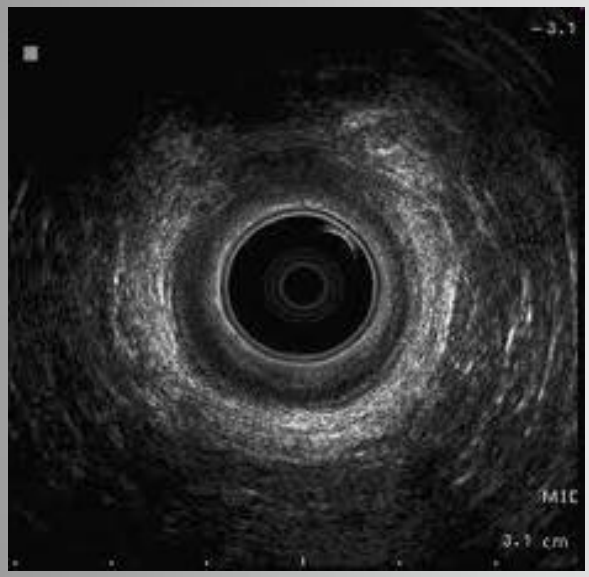


# FUNCTIONAL PROBLEM

| Type of incontinence | Never | Rarely | Sometimes | Usually | Always |
|---|---|---|---|---|---|
| Solid | 0 | 1 | 2 | 3 | 4 |
| Liquid | 0 | 1 | 2 | 3 | 4 |
| Gas | 0 | 1 | 2 | 3 | 4 |
| Wear Pad | 0 | 1 | 2 | 3 | 4 |
| Lifestyle altered | 0 | 1 | 2 | 3 | 4 |

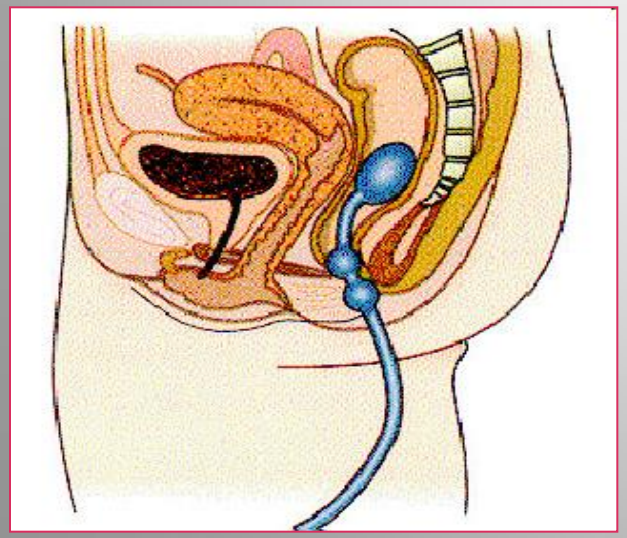


3,4%- ANAL INCONTINENCE WITHOUT ANAL SPHINCTER DEFECT

AGING

# INVOLVED

# CAN EPISIOTOMY HARM THE INNERVATION OF THE EXTERNAL ANAL SPHINCTER?

Episiotomy is the most common obstetric surgical intervention; **right side mediolateral episiotomy** is usually recommended.

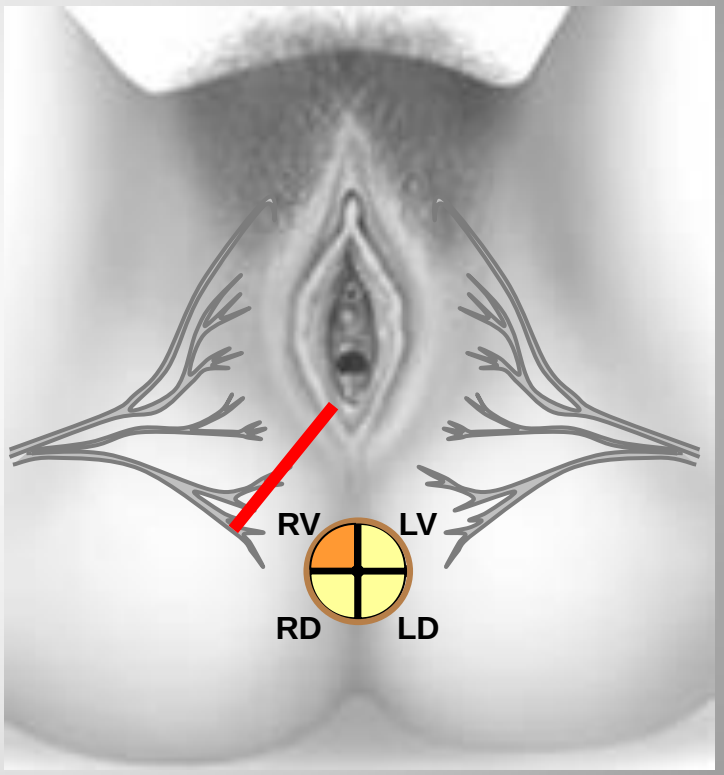


Wietek BM. Asymmetric Sphincter Innervation is Associated With Fecal Incontinence After Anal Sphincter Trauma During Childbirth. Neurourol. Urodyn, 2007 26:134 -139

# FUNCTIONAL ASYMMETRY OF PELVIC FLOOR INNERVATION HAS BEEN SHOWN TO EXIST IN HEALTHY SUBJECTS.

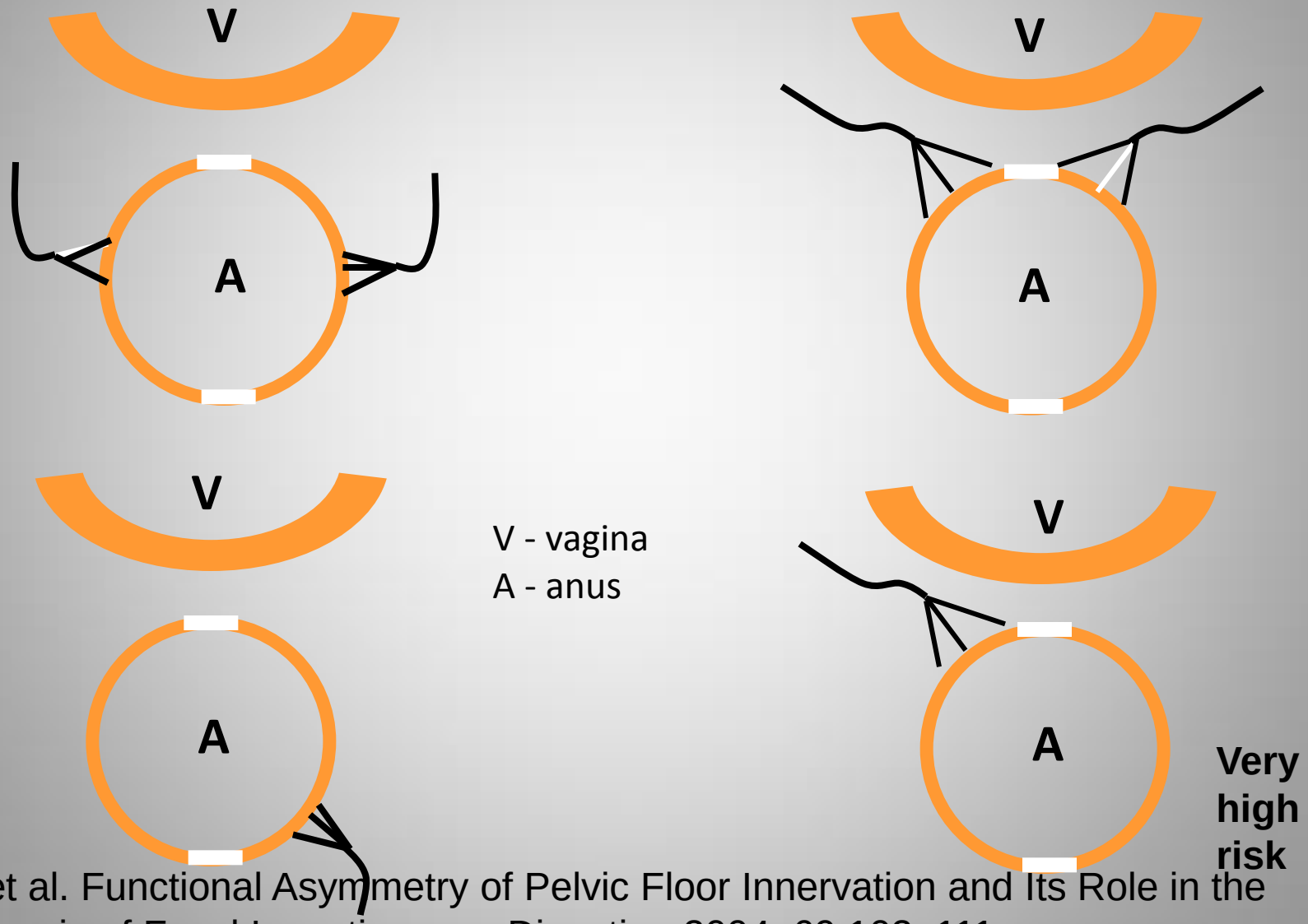


Enck P et al. Functional Asymmetry of Pelvic Floor Innervation and Its Role in the Pathogenesis of Fecal Incontinence. Digestion 2004; 69:102–111

# INNERVATION ZONE

Motor Unit

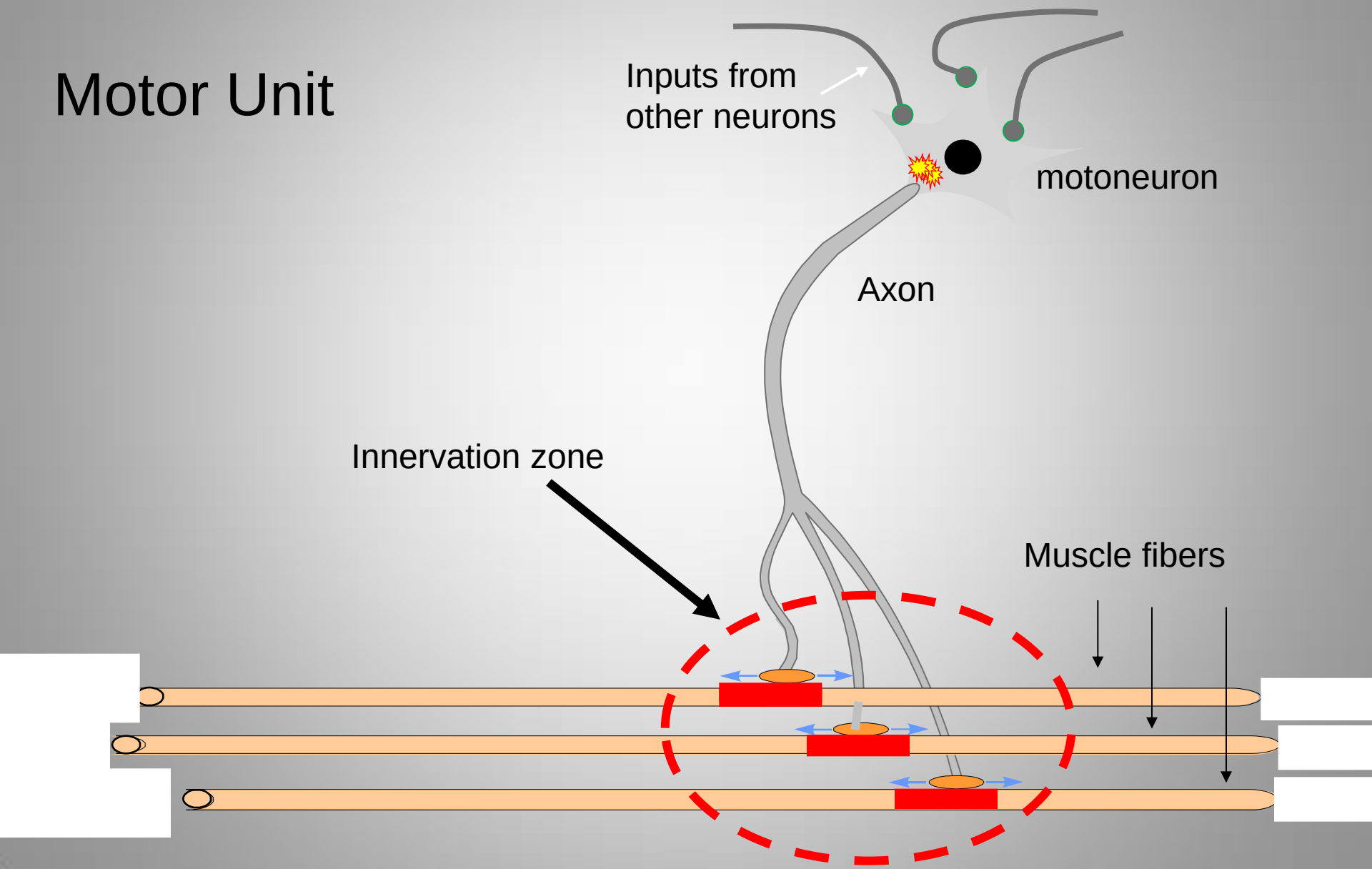

# EMG SIGNAL DETECTION FROM THE EXTERNAL ANAL SPHINCTER

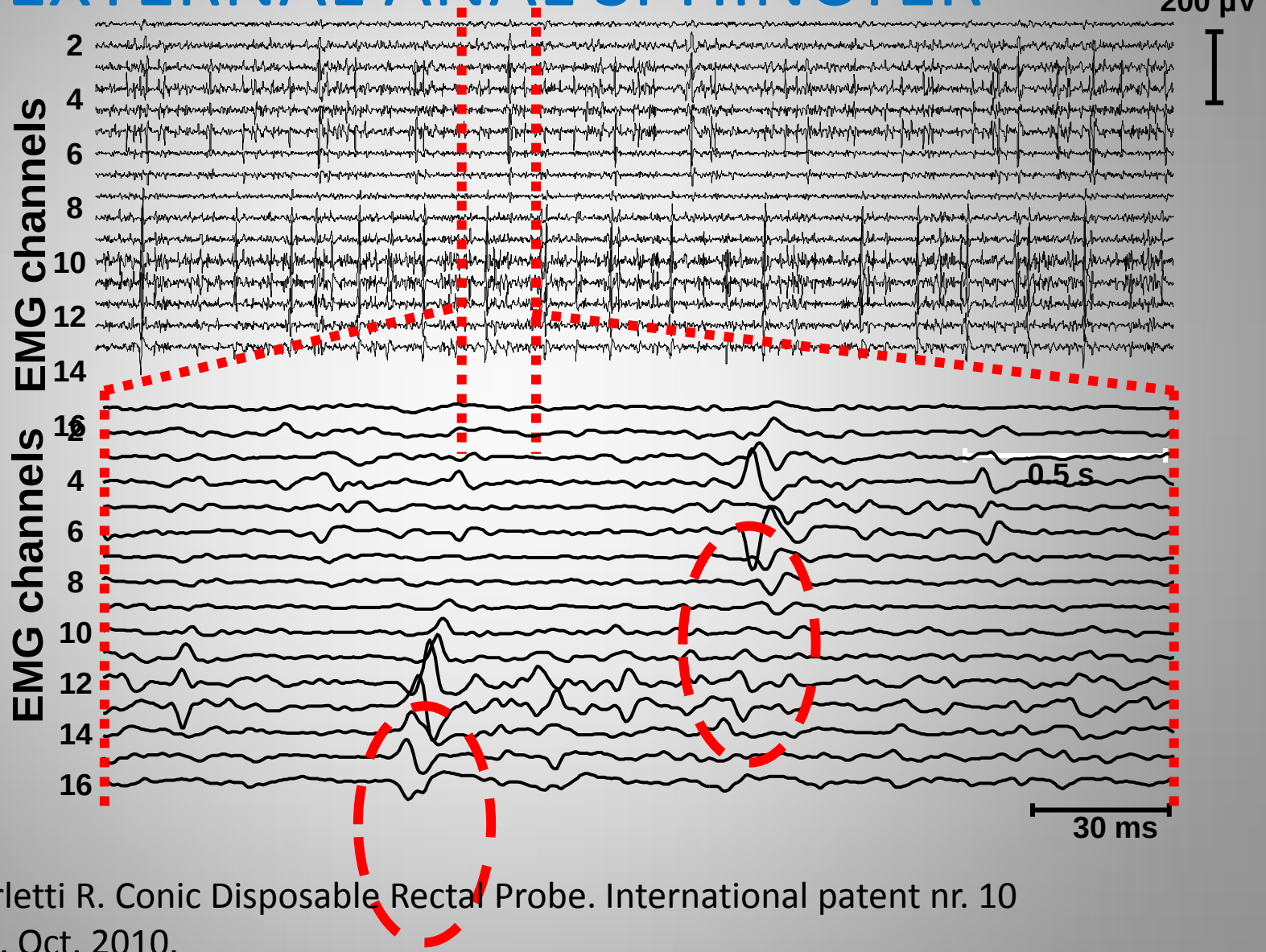

# IDENTIFICATION OF IZS

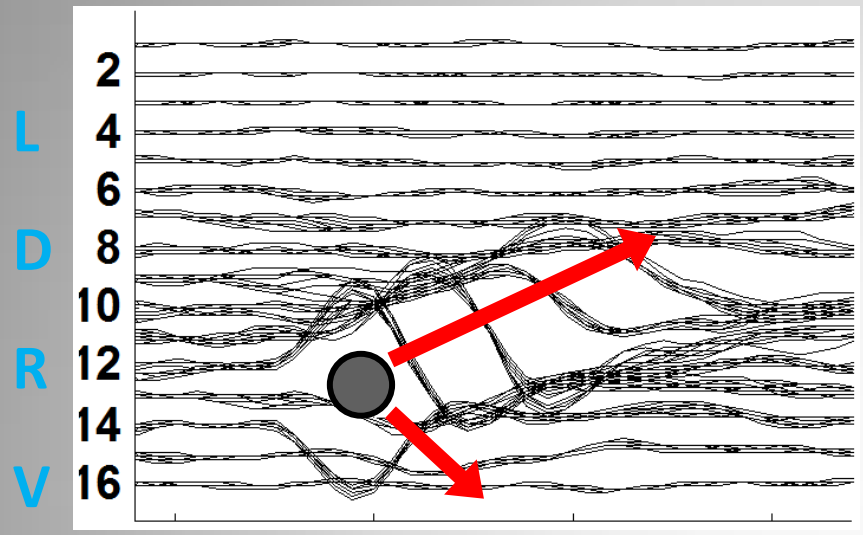


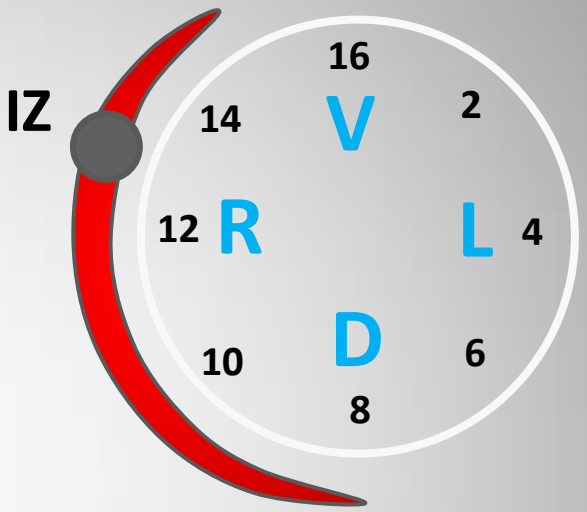


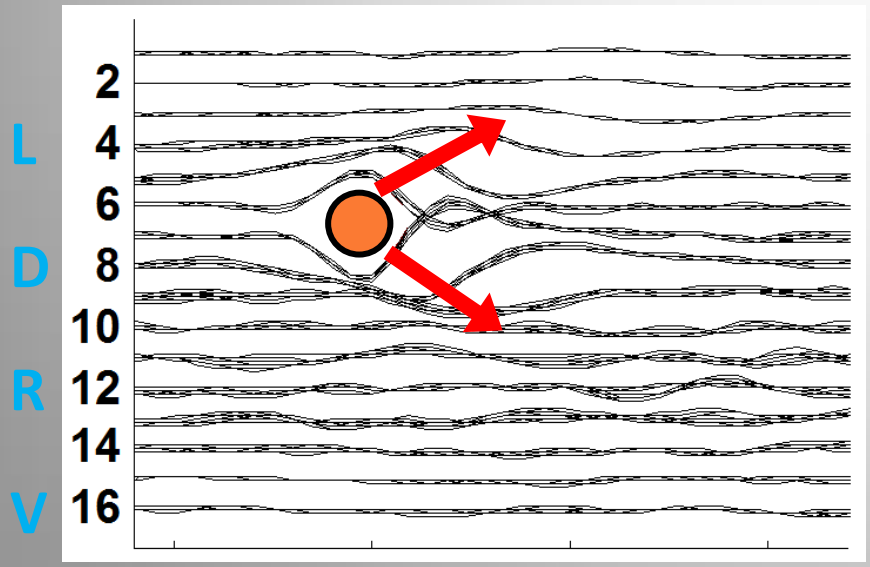


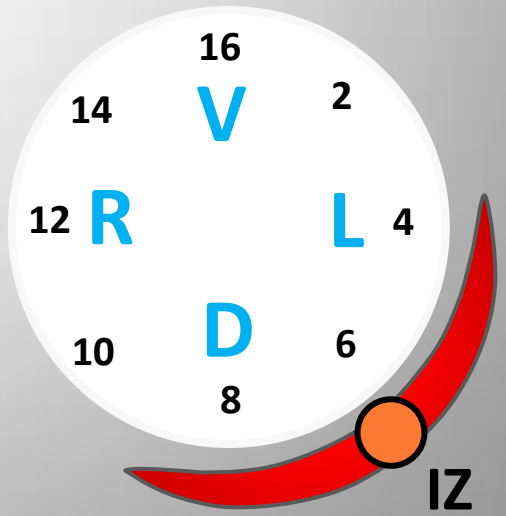

# STUDY DESIGN

- **33** PRIMIPAROUS WOMEN, WITH MEDIOLATERAL EPISIOTOMY ON THE RIGHT SIDE.
- THE SUBJECTS WERE DIVIDED INTO **THREE GROUPS** ACCORDING TO THE INNERVATION:
  - **PREDOMINATELY RIGHT**
  - **SYMMETRICAL**
  - **PREDOMINATELY LEFT**
- THE **NUMBER OF INNERVATION ZONES** (IZs) OF EXTERNAL ANAL SPHINCTER BEFORE AND AFTER DELIVERY WAS COMPARED.

# OUR RESULTS

Wilcoxon signed rank test:
$p < 0.05$

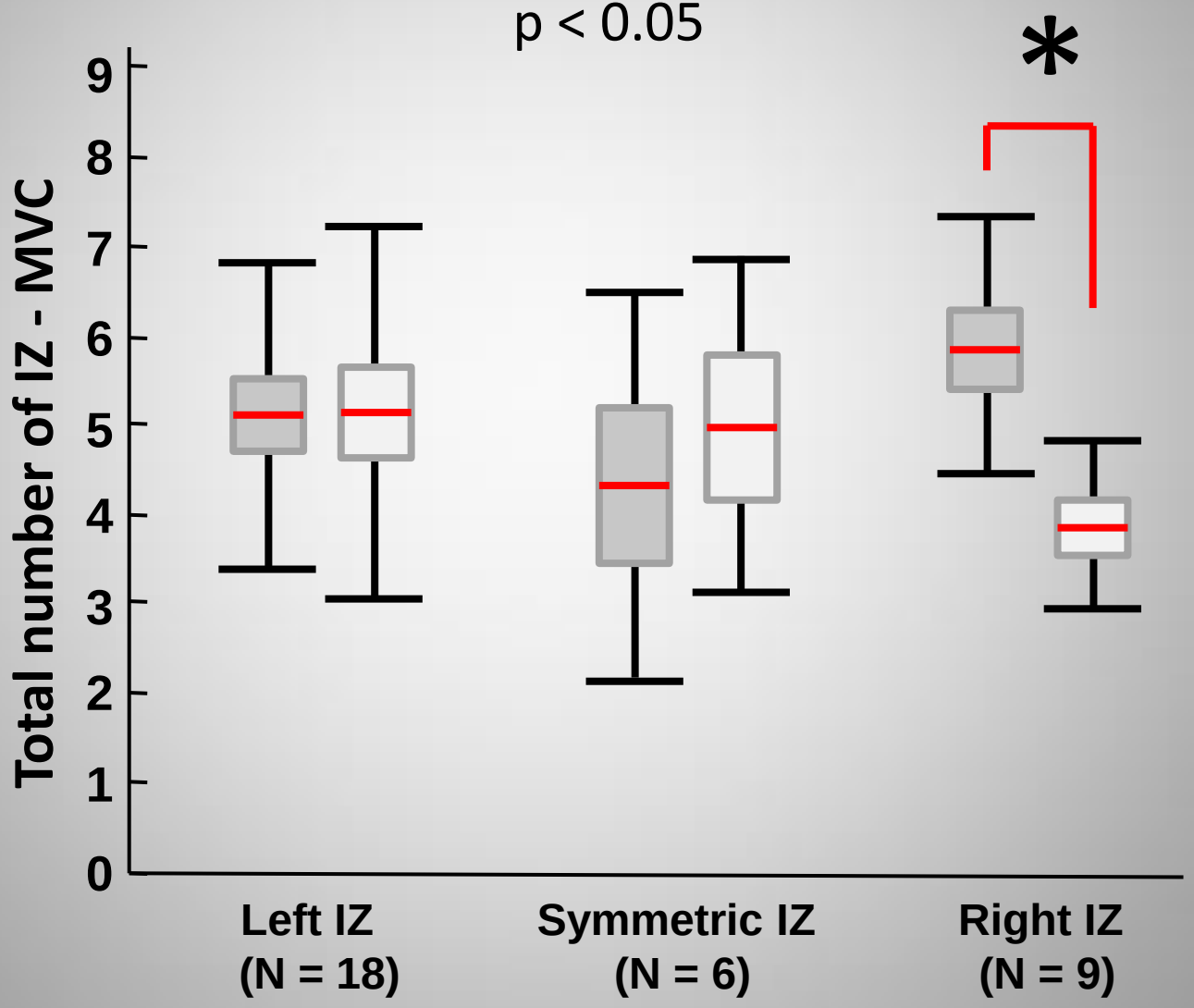

# CONCLUSIONS

- MEDIO LATERAL **EPISIOTOMY REDUCES THE NUMBER OF INNERVATION ZONES** (IZ) ON THE SIDE WHERE THE INCISION IS PERFORMED.
- A NOVEL TECHNIQUE – **SURFACE ELECTROMYOGRAPHY** - FOR NON INVASIVE ASSESSMENT OF THE INNERVATION PATTERN OF THE EAS IS AVAILABLE.
- LOCATION OF INNERVATION ZONES WITH ANAL SPHINCTER ELECTROMYOGRAPHY BEFORE DELIVERY COULD ALLOW **CHOOSING THE LEAST INVASIVE SIDE** FOR EPISIOTOMY.

- **FOLLOW-UP STUDIES** ARE NECESSARY TO EVALUATE THE POSSIBLE RE-INNERVATION OF THE EAS
- QUESTION STILL OPEN : IS INCONTINENCE MORE LIKELY TO OCCUR IN PATIENTS WHO EXPERIENCED A SEVERE LOSS OF INNERVATION?

SHOULD WE ASSES FUNCTION AS WELL AS ANATOMY?

# References for surface EMG on EAS


1. Merletti R, Bottin A, Cescon C, Farina D, Mesin L, Gazzoni M, et al. **Multichannel surface EMG** for the non-invasive assessment of the anal sphincter muscle. (2004) Digestion;69:112–22.
2. Enck P, Hinninghofen H, Wietek B, Becker HD. **Functional asymmetry of pelvic floor innervation** and its role in the pathogenesis of fecal incontinence. (2004) Digestion;69(2):102–11.
3. Enck P, Hinninghofen H, Merletti R, Azpiroz F. **The external anal sphincter and the role of surface electromyography**. (2005) Neurogastroenterol Motil;17(Suppl. 1):60–7.
4. Cescon C. **Automatic location of muscle innervation zones** from multi-channel surface EMG signals. (2006) In: Proc IEEE int workshop on medical measurement & applications;. p. 20–1.
5. Cescon C, Bottin A, Fernandez Fraga XL, Azpiroz F, Merletti R (2008). **Detection of individual motor units of the puborectalis muscle** by non-invasive EMG electrode arrays. Journal of electromyography and kinesiology : official journal of the International Society of Electrophysiological Kinesiology, 18(3), 382–9.
6. Mesin L, Gazzoni M, Merletti R. Automatic **localisation of innervation zones**: A simulation study of the external anal sphincter. (2009) J Electromyo Kinesiol;19:413–21.
7. Enck P, Franz H, Davico E, Mastrangelo F, Mesin L, Merletti R. **Repeatability of innervation zone identification** in the external anal sphincter muscle. (2010) Neurourol Urodyn;29(3):449–57.
8. Cescon C, Merletti R. Conic disposable **rectal probe**. (2010) International **patent** nr.TO2009A000814, October.
9. Cescon C, Merletti R, Ullah K. Metodo perfezionato per l'identificazione di una zona di innervazione (2014) **patent.**
10. Cescon C, Mesin L, Nowakowski M, Merletti R (2011). **Geometry assessment** of anal sphincter muscle based on monopolar multichannel surface EMG signals. Journal of electromyography and kinesiology : official journal of the International Society of Electrophysiological Kinesiology, 21(2), 394–401. doi:10.1016/j.jelekin.2010.11.003
11. Cescon C, Raimondi EE, Zacesta V, Drusany-Staric K, Martsidis K, Merletti R. **Characterization of the motor units** of the external anal sphincter in pregnant women with multichannel surface EMG. (2014) Int Urogynecol J; in press. 10.1007/s00192-014-2356-3.
12. Cescon C, Riva D, ZacestaV, Drusany-Staric K, Martsidis K, Protsepko O, et al. **Effect of vaginal delivery on the external anal sphincter muscle** innervation pattern evaluated by multichannel surface EMG: results of the multicentre study TASI-2. (2014) Int Urogynecol J; in press. http://dx.doi.org/10.1007/s00192-014-2375-0.